

# The IRIS

ARTISAN. / ARTI FLEX.

- Optimal location for refractive correction
  - The toughest tissue within the eye
- Phakic, Aphakic, Trauma and Pediatric

國際知名植入式微型晶片大廠OPHTEC BV 特刊

SEM of posterior iris



post@meditools.no  
Tlf: 40 17 40 16

# Surgeon Testimonials



**Dr. I. Ahmed, Canada**

"The iris claw permits stable fixation of the lens, performed in a very efficient manner with minimal tissue manipulation or suture requirement"



**Dr. M. Landesz, The Netherlands**

"The ARTIFLEX" has the same 'wow-effect' one day postoperative as the lasik has"



**Dr. C. Budo, Belgium**

"The ARTI FLEX" shares the exceptionally good refractive and visual outcomes that have been associated with the ARTISAN" IOL and over time is expected as well to be free from complications such as induction of cataract formation and pupil distortion that have occurred with other phakic IOLs"



**Dr. F.J. Potgieter, South Africa**

"The ARTI FLEX" offer the surgeon the unique advantage of a large diameter iris fixated phakic prosthesis combined with small incision surgery, while providing the patient with quick and stable visual recovery as well as the same low complication rates as seen with the ARTISAN" phakic IOL"



**Prof. Choun-Ki Joo, South Korea**

"I can observe an whole aperture of the lens in the patient's eye during the follow up period. So, I understand a patient's condition completely. I think it would be main advantage of iris claw phakic IOL compared with posterior chamber phakic IOL."



**Dr. R. Ruiz Mesa, Spain**

"With the ARTIFLEX" Torie Lens and its option to be implanted through only 3mm, at last I've found a phakic lens, which I have long needed for my patients: guaranteeing ease of procedure, rapid visual recovery and especially. safety of rotational stability independent of the calculation"



**Dr. S. Fukuoka, Japan**

"The ARTISAN" and ARTIFLEX" lenses are especially reliable to use in cases with astigmatism because the IOLs can be fixated stable on the iris without rotation"



**Dr. R. Spirig, Switzerland**

"ARTIFLEX" implantation is absolutely astigmatism neutral. The ARTIFLEX" can therefore be implanted not only in cases with high myopia, but also in cases with low myopia, where it is especially important to avoid any surgery-induced astigmatism. We experienced a very high degree of satisfaction in this group of patients who prefer to have refractive surgery with a reversible procedure rather than with a Lasik method"



**Dr. J.L. Güell, Spain**

"Our 5 year experience with the ARTIFLEX" have been extremely positive, being the earlier refractive rehabilitation the most successful and safe model. Hopefully, the long term safety data will be as good as the one that we have had with the PMMA implant"



**Prof Dr. J. Venter, UK**

"The ARTISAN" has always been with Toric ARTIFLEX" is outstanding" achieved

國際知名植入式微型晶片大廠OPHTEC BV 特刊  
**台灣唯一指定推薦醫師!**



**Dr. Huang Wei Jen, Taiwan**

"Once I trusted that the results were very good, I jumped at the opportunity of using ARTISAN" and, about a year ago. ARTI FLEX"




**Dr. L. Zabala, Portugal**

"The Torie ARTI FLEX" has all the advantages of the foldable anterior chamber phakic IOLs combined with the possibility of accurately correct a wide range of astigmatic power providing not only an excellent refractive result but also very good visual outcome"



# ARTIFLEX. Myopia



## Next Generation of Iris Fixated IOLs

ARTIFLEX® has a foldable lens body thus permitting a small incision.

ARTIFLEX® offers a better predictability and faster recovery



## Features & Benefits

- Iris Fixation
- One size fits all
- Small incision, 3.2 mm;  
Controlled folding and unfolding
- Reversible treatment
- Aspherical edge design
- Optimal clearance from vital tissues
- Large optical zone

## // Specifications

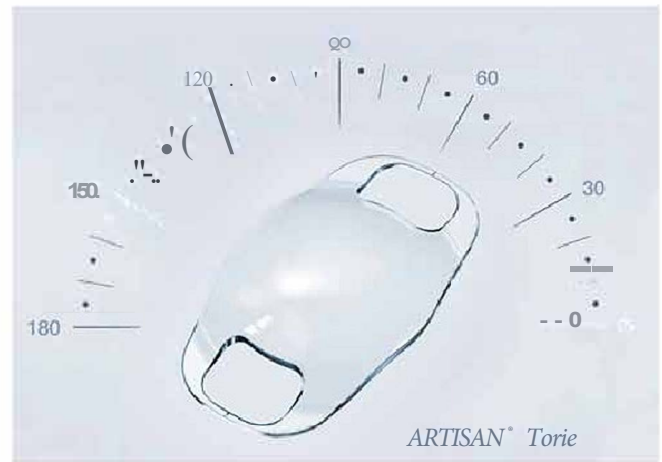ARTIFLEX® PIOL		Optic Material	Haptic Material	Total Ø	Body Ø	Dioptric Powers
ARTIFLEX® Myopia Model 401		Polysiloxane	PMMA	8.5 mm	6.0 mm	-2.0 D to -14.5 D (as in increments)

# ARTISAN./ ARTIFLEX.Toric PIO LS



## Only Artisan/ Artiflex Torie stop rotation

The ARTIFLEX® Torie PIOL is the latest extension of the successful ARTISAN® concept. It combines a spherical and cylindrical correction for low, moderate and high myopic eyes. The flexibility, extensive history and biocompatibility - *longer than any other foldable material* - of the silicone optic enables implantation through a small incision, which results in almost no induced astigmatism as well as fast recovery.



## Features & Benefits: **NO rotation postop**

### // Specifications

ARTISAN® Torie PIOL	Material	Optic	Body	Dioptric Powers
Positive Cylinder Models: S 90°	PMMA	8.5mm	5.0mm	Cylinder: 1 to 75 Sphere: +6.5 D to -23.0 D (0.5 increments)
Negative Cylinder Models: S 90°	PMMA	8.5mm	5.0mm	Cylinder: -1 to -75 Sphere: +7.5 D to -22.0 D (0.5 increments)

ARTIFLEX® Torie PIOL	Optic Material	Haptic Material	Total (I)	Body (I)	Dioptric Powers
ARTIFLEX Torie PIOL S	Polysiloxane	PMMA	8.5mm	6.0mm	Cylinder: -1.0 to -5.0 Sphere: -1.0 D to -13.5 D (0.5 increments)
ARTIFLEX Torie PIOL 90°	Polysiloxane	PMMA	8.5mm	6.0mm	



# ARTISAN®/ ARTIFLEX® Instruments

## Artisan Instruments



OD 125 ARTISAN•/ ARTIFLEX• Disposable Enclavation Needle



D02 40 ARTISAN., Reusable Enclavation Forceps



D02 70 ARTISAN• Reusable Implantation Forcep Refractive, Long  
D02 72 ARTISAN• Reusable Implantation Forceps Refractive, Short



Do6 4 ARTISAN• Reusable Lens Manipulator Standard, straight



H65.12.003 ArtiFix Holding Forceps

## Artiflex Instruments



OD 125 ARTISAN•/ ARTIFLEX• Disposable Enclavation Needle



OD 110 ARTIFLEX• Disposable Insertion Spatula



OF 106 ARTIFLEX• Reusable Implantation Forceps Right



OF 105 ARTIFLEX• Reusable Implantation Forceps Left



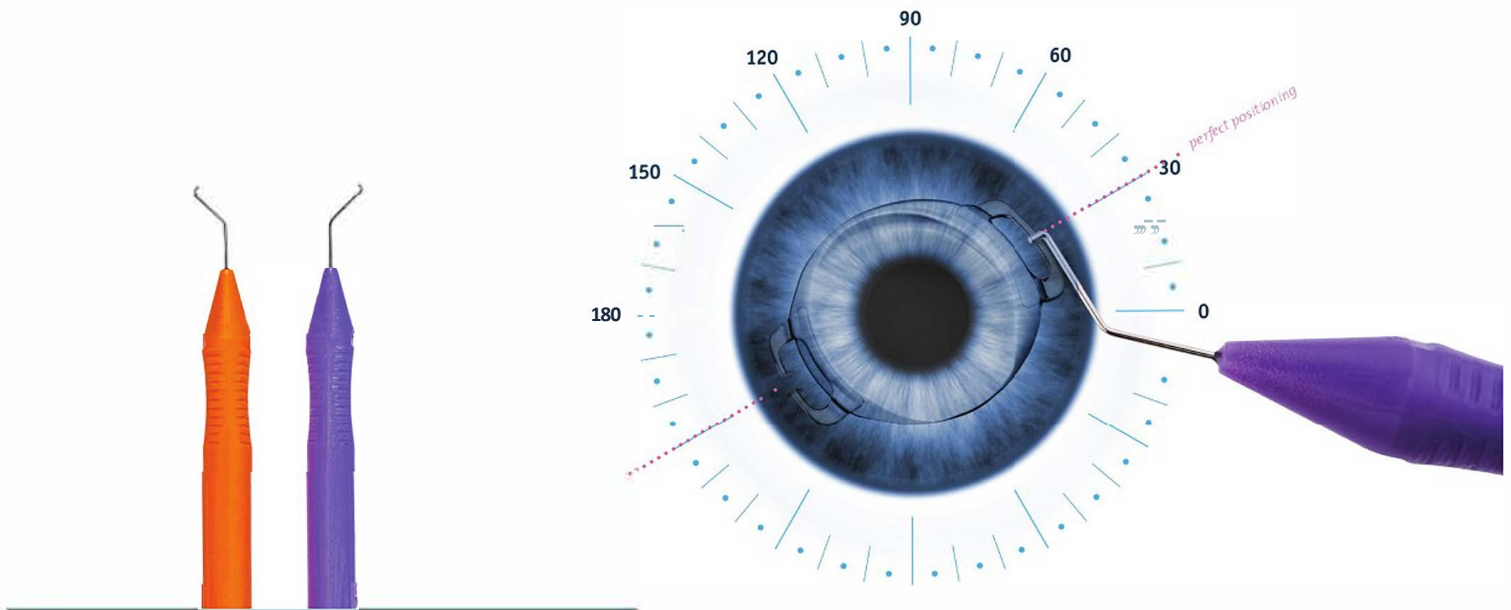
OF 15 ARTIFLEX• Reusable /Vanipulator



## Exact tissue every time

*Creates reproducible perfect "iris bridge"*

An enclavation system for the Artisan and Artiflex (Toric)(P)IOLs using the vacuum of your phaco machine to grasp a fold of iris tissue. The VacuFix consists of two disposable handles, one for the right side and one for the left. This will allow an optimal positioning and centration of the (T)(P)IOLs. The VacuFix tip with aspiration hole creates a perfect "iris bridge" with a controlled and reproducible amount of iris tissue. **Precision** for you and your patient is the key benefit, especially in toric Artisan/Artiflex surgery. For Artisan Aphakia cases the VacuFix adds **convenience**, as this system allows an easier grasp of iris tissue.



## II One System Fixates All

### Cataract Surgery

*ARTISAN<sup>K</sup> Aphakia /OL*

### Refractive Surgery

*ARTISAN<sup>K</sup> Myopia, Hyperopia*

*& Toric PIOL;*

*ART/FLEX Myopia & Toric PIOL*

## II Main Features & Benefits

**Vacuum enclavation for best positioning and centration of the (toric) (P)IOLs**

**The VacuFix tip with aspiration hole creates a perfect "iris bridge"**


- Fixed and reproducible amount of iris tissue

**Preformed curved tip of the VacuFix makes it easy to reach the enclavation site**

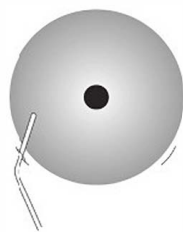
**The VacuFix is compatible with all phaco machines**

# SURGICAL PROCEDURE ARTISAN<sup>®</sup>

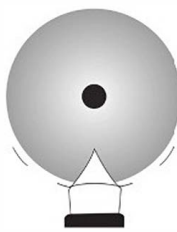
## with Vacufix<sup>™</sup> and Enclavation Needle



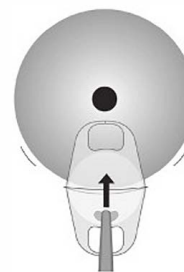
1 Make paracenteses at 10 and 2 o'clock, pointing towards the fixation site



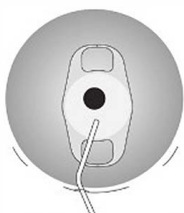2 Constrict the pupil; then introduce viscoelastic material, sodium hyaluronate (e.g. ArtiVisc or ArtiViscPlus)



3 Perform a main incision of 52 mm or 62 mm depending on the optic diameter of the lens



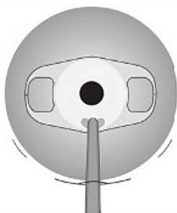
4 Introduce the lens into the anterior chamber



5 Add some viscoelastic material on top of the lens

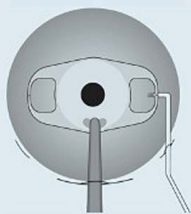


6 Rotate the lens into the horizontal position

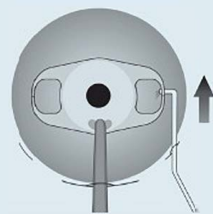


7 Center the lens on the pupil; grasp the lens at the edge of the optic

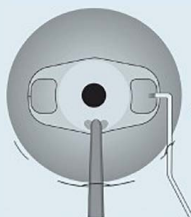
### // Vacufix<sup>™</sup>



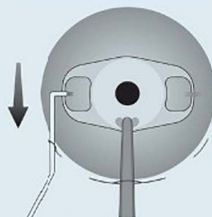
8 Introduce the VacuFix through the paracentesis and make sure the hole of the VacuFix is placed underneath the slot of the claw. Create vacuum



9 Move the VacuFix with the occluded iris forward to the inferior part of the claw

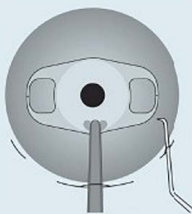


10 Lift the VacuFix through the inferior claw and pull the VacuFix with the iris fold through the slot of the claw

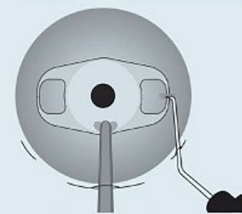


11 Repeat the lens fixation to the iris on the other side

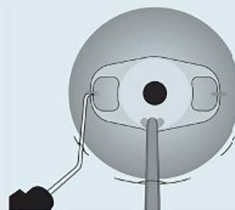
### // Enclavation Needle



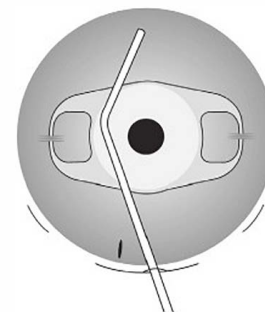
8 Introduce the Enclavation Needle through the paracentesis



9 Make a "snow ploughing" movement by moving the Enclavation Needle downward and forward at the same time, creating a fold of iris tissue just under the claw of the lens



10 Repeat the lens fixation to the iris on the other side

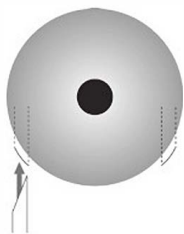


11/12 Make a peripheral iridectomy (or iridectomy), remove the viscoelastic material and close the main incision

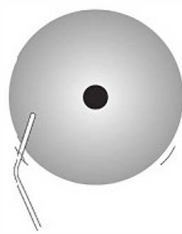


# SURGICAL PROCEDURE ARTIFLEX<sup>®</sup>

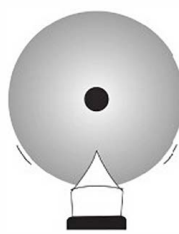
## with VacuFix<sup>™</sup> and Enclavation Needle



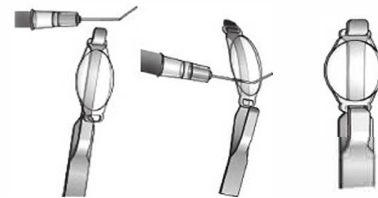
1 Make paracenteses at 10 and 2 o'clock, pointing towards the fixation site



2 Constrict the pupil; then introduce viscoelastic material, sodium hyaluronate (e.g. ArtiVisc or ArtiViscPlus)



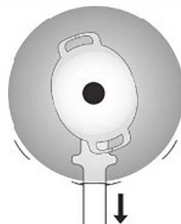
3 Perform a main incision of 3.2 mm



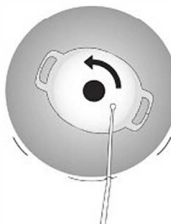4-6 Attach the Artiflex PIOL to the Insertion Spatula



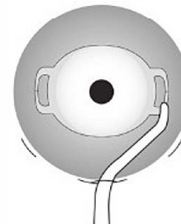
7 Irrigate the lens with saline; introduce the lens into the anterior chamber with the Insertion Spatula



8 Retract the Insertion Spatula; use a forceps to exert counter pressure

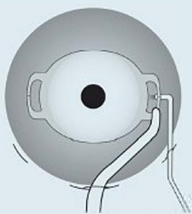


9 Add some visco on top of the lens and rotate the lens into the horizontal position




10 Center the lens on the pupil; grasp the lens at the superior claw with the Artiflex Holding Forceps

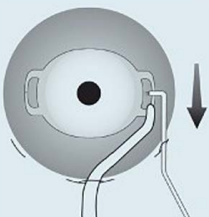
### // VacuFix<sup>™</sup>



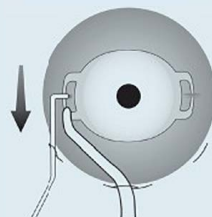
11 Introduce the VacuFix through the paracentesis and make sure the hole of the VacuFix is placed underneath the slot of the claw; create vacuum



12 Move the VacuFix with the occluded iris forward to the inferior part of the claw

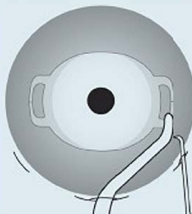


13 Lift the VacuFix through the inferior claw and pull the VacuFix with the iris fold through the slot of the claw

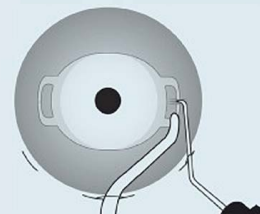


14 Repeat the lens fixation to the iris on the other side

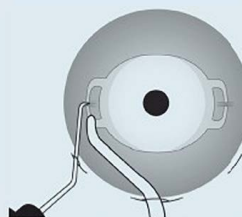
### // Enclavation Needle



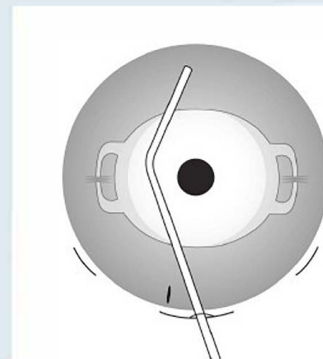
11 Introduce the Enclavation Needle through the paracentesis



12 Make a "snow ploughing" movement by moving the Enclavation Needle downward and forward at the same time, creating a fold of iris tissue just under the claw of the lens



13 Repeat the lens fixation to the iris on the other side



14/15. Make a peripheral iridotomy (or iridectomy), remove the viscoelastic material and close the main incision



# ARTISAN"/ ARTIFLEX. overview

## Avoiding and Managing Complications;

### *Patient Selection Criteria - Proper Enclavation*

All refractive procedures have a common concept:

**Careful Patient selection criteria are critical to successful outcomes.**

The ARTISAN /ARTIFLEX, like all refractive procedures, has "rules" to ensure success. We present here a consolidation of critical measurements. For a more comprehensive discussion please review Ophtec training manual.

Additionally, refractive procedures, like all surgical procedures, complications can happen. How to manage these is most important. We also address adverse events that can happen.

#### **ARTISAN**

##### *Endothelial health*

Minimum preoperative anterior chamber depth is 3.0 mm from epithelium, based on a minimum critical distance of 1.0 mm. (reference to critical distance tables in training manual).

##### *Minimum preoperative endothelial cell density (ECD) depending on patient age:*

<25 years of age	2800 cells/mm <sup>2</sup> ;
26 to 30 years of age	2650 cells/mm <sup>2</sup> ;
31 to 35 years of age	2400 cells/mm <sup>2</sup> ;
36 to 45 years of age	2200 cells/mm <sup>2</sup> ;
>45 years of age	2000 cells/mm <sup>2</sup> ;

After lens implantation, there should be an annual monitoring of the ECD. Patients have to be instructed not to rub their eyes, as this can cause damage to the endothelium.

##### *Achieving good visual outcome*

- Accurate determination of preoperative refraction is crucial for achieving good refractive outcomes. A clinically significant difference between cycloplegic and manifest refraction is a contraindication.
- Pupil sizes in scotopic conditions should be:;; body size of PIOL +1.0 mm to reduce the risk of glare and halos.

##### *Avoiding complications*

An abnormally cone shaped, bulging iris (typical for hyperopic eyes) is a contraindication, as it can cause formation of synechiae. For a complete overview of indications, contraindications and surgical technique see training manual).

#### **ARTIFLEX**

##### *Endothelial health*

Minimum preoperative anterior chamber depth is 3.2 mm from epithelium, based on a minimum critical distance of 1.3 mm.

##### *Minimum preoperative endothelial cell density (ECD) depending on patient age:*

<25 years of age	2800 cells/mm <sup>2</sup> ;
26 to 30 years of age	2650 cells/mm <sup>2</sup> ;
31 to 35 years of age	2400 cells/mm <sup>2</sup> ;
36 to 45 years of age	2200 cells/mm <sup>2</sup> ;
>45 years of age	2000 cells/mm <sup>2</sup> ;

After lens implantation, there should be an annual monitoring of the ECD. Patients have to be instructed not to rub their eyes, as this can cause damage to the endothelium.

##### *Achieving good visual outcome*

- Accurate determination of preoperative refraction is crucial for achieving good refractive outcomes. A clinically significant difference between cycloplegic and manifest refraction is a contraindication.
- Pupil sizes in scotopic conditions should be:;; 7.0 mm to reduce the risk of glare and halos.

##### *Avoid complications*

- Select patient with flat irises. A convex, bulging or volcano shaped iris is a contraindication, as it can cause formation of deposits or synechiae.
- A correct surgical technique has to be used in order to avoid deformation of the PMMA haptics.

##### *If Deposits on the optic surface appear*

Non-pigment deposits can be observed in a small percentage of patients - the exact reasons have not been established as this occurs rarely and follows no distinct pattern. The deposits are random and can appear in one of a patient's eyes and not in the fellow eye.

The deposits are usually observed between one and three months postop and slowly diminish after this period. There are no more deposits observed after one postoperative year, even in the cases that were not treated with corticosteroids.

The discussions among the researchers suggest the probable cause of this phenomenon to be friction between the posterior lens surface and the iris, along with an implantation technique that is more difficult than that of the ARTISAN lens. However we have not been able to confirm the root cause due to very limited occurrence and randomness.

*The following conclusions/guidelines were elicited from these discussions:*

- 1 Eyes with a shallow ACD (<math>< 3\text{mm}</math>) should be avoided. It is additionally of great importance that the iris is flat. Eyes with a convex, bulging or volcano shape must definitely be avoided. It is also advised that the pre-op examination techniques such as Scheimpflug photography or a OCT scan should be used. Unfortunately, it seems that not every suitable ARTISAN candidate is automatically a suitable ARTIFLEX candidate as well. Also, the iris of patients with myopia is not always evenly flat.
- 2 Excessive manipulation during surgery can lead to more deposits, but taking the learning curve of the technique into account, this should improve after a number of implantations. Enclavating an iris fold that is too large in the claw should be avoided. A large fold causes the lens to adhere more tightly to the iris. Use of the VacuFix will ensure the exact amount of iris tissue is enclavated everytime.
- 3 Administration of preventative corticosteroids should be started after the implantation. This treatment must be maintained for four weeks. A schedule is cited here below. Some doctors administer a depo injection at the end of the implantation procedure.

*ART/FLEX postoperative medication:*

*Antibiotics:*

- 1 drop of topical antibiotics 3 times daily during the first postoperative week, gradually reduced during 2 weeks.

*Corticosteroids:*

- 1 drop of strong-working topical steroids (for example, dexamethasone or fluormetholon) 3 times daily during the first four postoperative weeks. A peroperative depo injection of Depo-Medrol is optional.


*To prevent excessive eye pressure:*

Diamox or Betagan as needed.


In the event that a patient does develop deposits that impede vision, the doctor can treat the deposits with a brief course of corticosteroid treatment. This should cause the deposits to quickly disappear and the vision to re-emerge.

If the deposits do return or do not disappear, a re-enclavation should be considered. In some cases, this has been known to stop these returning symptoms. If the symptoms do not stop and continue to return, this can lead to an explantation.


## How to properly Enclavate the iris




Notice that the "claws" are perfectly aligned.



**PROPER technique:** Enclavate iris tissue by bringing the iris tissue thru the opposite "claw" from forceps



**WRONG technique:** DO NOT enclavate the iris where the forceps is being held



See damage caused by improper enclavation

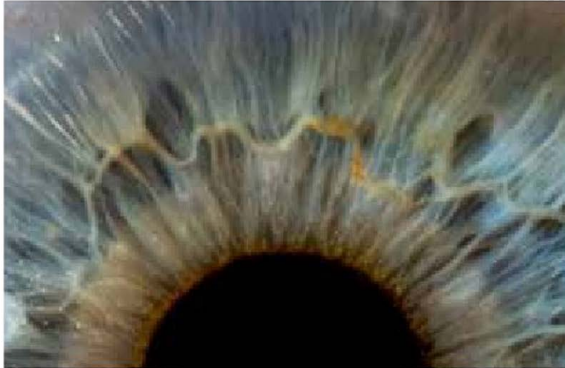# **ARTISAN<sup>®</sup> and ARTIFLEX<sup>®</sup> Phaldc IOLs:**

**Clinical Evidence Continues to Support  
Biocompatibility and Design Features**

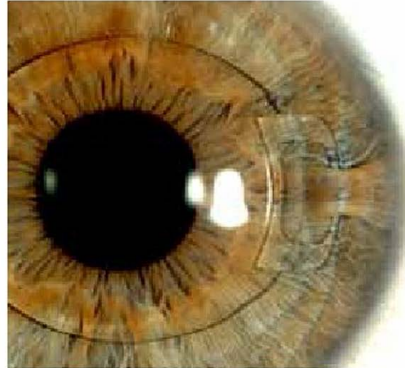
**Comprehensive overview of literature: Endothelial cell change after Artisan/Artiflex implantation**



# Iris structure



The mid-peripheral iris follows the same radial pattern as the vascular and nerve system of the eye.



This pattern of tissues allows the dips of the Artisan/Artiflex to "weave" into the tissue. *Photo: Dr Chazalon*

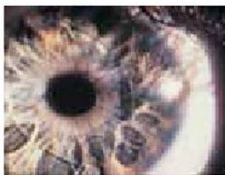# Iris Anatomy



**// Vascular supply**  
Arterial inflow & venous backflow - Radially oriented terminal end-arteries - No connection between individual end-arteries.



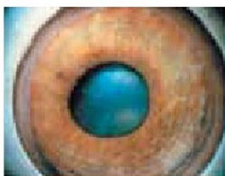**// Nerve system**  
The nerve system runs parallel to the vascular supply - No nerve/vascular damage caused by iris fixation of Artisan/Artiflex.



**// Pigment layer**  
Blue eyes: deep brown pigment on rear iris surface only.



**// Post removal Artisan After 6 yrs. in eye**  
No sign of pigment loss at rear side of the iris at the sites where Artisan was clipped.



Brown eyes: deep brown pigment on rear iris surface + pigment within the iris stroma.

# Objective

Educate the ophthalmic community with a review of publications involving endothelial cell count analysis after Artisan implantation, and compare safety outcomes to ICL.

## Introduction

Function of the endothelium

Most of the cells in our body have the capacity to divide. When a cell dies, other cells will divide to replace the ones that were lost. This process is not seen in the human cornea because the corneal endothelium has a limited proliferation capacity. Instead the cells simply enlarge and spread to fill the area where the dead cells were located. This method of 'healing' the endothelium works to a certain threshold. When there are too few cells to maintain the barrier between the cornea and the aqueous humor, fluid freely enters the cornea, causing edema and corneal blindness<sup>1</sup>.

Endothelial Cell Consideration

Endothelial cell count is therefore an important issue in refractive surgery. Research has shown that the endothelial cell density (ECD) of the adult cornea decreases at a rate of 0.6% per year.<sup>2</sup> To limit further endothelial cell loss, the Artisan and Artiflex lenses are designed to allow for a safe distance between the endothelium and the rim of the lens. A strict patient selection is also important; to prevent endothelium related complications, patients should have a large enough anterior chamber and sufficient endothelial cell count. After implantation, the endothelium should be monitored annually for as long as the lens is in the eye.

The subject of endothelial cell loss after Artisan implantation is a hot topic. It is being discussed on international congresses and there are many different opinions. Some doctors do not want to implant the Artisan lenses because of the risk to the endothelium, while others say that the lens is absolutely safe to use.

Table 1: Overview of Artisan literature with data about the endothelium. Publications in bold are 11:2:50.

				Reported cell change end of study (Annual cell change) (%)
Asano <sup>1</sup>	Myopia	2	44	-2.86 (-1.45)
Benedetti <sup>1</sup>	Myopia	5	49	-9.0 (-1.87)
Guell <sup>1</sup>	Myopia 206	5	101	-11.4 (-2.39)
Guell <sup>1</sup>	Myopia 204	5	173	-10.9 (-2.38)
Landesz <sup>4</sup>	Myopia	2	78	61 (31)
Menezo <sup>5</sup>	Myopia	5	61	-10.51 (-2.2)
Moshirfar <sup>1</sup>	Myopia	2	85	-6.5 (-3.3)
Tahzib <sup>1</sup>	Myopia	10	89	-8.86 (-0.92)
Tehrani <sup>1</sup>	Myopia	3	28	8 (-2.74)
Saxena <sup>9</sup>	Myopia	7	13	-12.6 (-1.9)
Silva <sup>10</sup>	Myopia	5	26	-14.05 (-2.99)
Bartels <sup>11</sup>	Torie	2	54	-0.3 (-0.15)
Guell <sup>1</sup>	Torie	3	84	-3.6 (-1.21)
Bartels <sup>12</sup>	Hyperopia	2	47	-1.00 (-0.5)
Giell <sup>3</sup>	Hyperopia	4	41	-6.4 (-1.64)
Saxena <sup>13</sup>	Hyperopia	1	16	-11.70 (-4.10)
Tehrani <sup>1</sup>	Hyperopia	3	12	-2.54 (-0.85)
Doors <sup>14</sup>	Artisan/Artiflex myopia	7	18	-5.02 (-0.73)
Qasem <sup>15</sup>	Myopia/hyperopia/toric	5	151	"No significant loss"

This document is an attempt to present the endothelial cell loss data after Artisan implantation as described in literature.

The purpose is to form an objective opinion about the safety of the Artisan for the endothelium based on data in the literature, rather than based on hearsay.

Limitations of endothelial cell counts

When interpreting endothelial cell data, it should be pointed out that endothelial cell measurements with their limitations can be difficult to put in perspective. Measurements taken on the same patients show a large grade of variety of 7% on average<sup>16</sup>, meaning that another measurement on the same eye will result in a different outcome. If the endothelial cell loss is analyzed by a different investigator this already accounts for several percentages difference in cell loss. Furthermore, since there are no standardized methods to evaluate endothelial cell loss (every center uses different combinations of equipment and analysis techniques), it is difficult to compare results from different studies. Surgical technique also influences the surgery related cell loss after the implantation. These limitations have to be kept in mind when interpreting the below results of the literature search.

## Literature search

To get an objective idea of the actual cell loss percentages for Artisan in literature, an overview has been generated in figure 1. Peer reviewed articles are included which have a follow-up time of 2 years or more: Ophtec study reports were excluded to prevent possible bias in objectivity of the reporters. As a result, 15 articles were found (table 1).

## Analysis

Average

The average annual endothelial cell change in the literature was -1.59% (table 2), around 1% more than the physiological loss of 0.6%.

Figure 1 shows that approximately two third of the studies reported a cell loss of less than 2 percent per year, the remaining publications reported a larger cell loss up to 4.1 % in one study. When grouping the publications per lens model, the average annual cell change with Artisan Myopia, Artisan Toric and Artisan Hyperopia was -1.58%, -0.68% and -1.77% respectively.

Table 2: Mean endothelial cell loss after Artisan implantation as presented in literature

Number of groups	N
Mean annual EC change	-1.59 %± 1.65
Mean annual EC change (studies n>50)	-1.18 %± 2.0
Range	+ 3.10 to -4.10 %

<sup>16</sup>Publications since the year 2000 were considered with a follow-up of at least 2 years, which included endothelial cell density analysis after Artisan implantation. Official Ophtec study publications were not included and when several publications reported of the same group of patients, the publication with the longest follow-up was selected. Single case reports were also excluded. This resulted in 15 publications reporting about 18 patient groups.

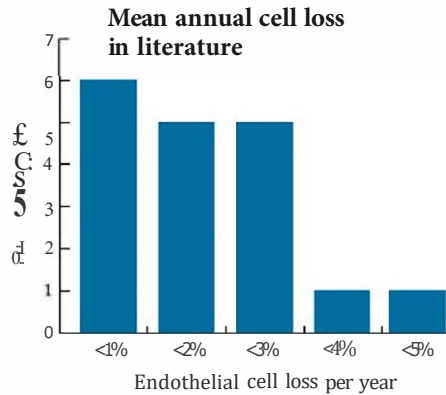


Figure 1 Percentages of annual endothelial cell loss after Artisan implantation as presented in literature. Publications since the year 2000 with minimum follow-up of 2 years were selected.

#### Large variation

It can be noted that there is a large variation in percentage cell loss between the articles, ranging from an annual loss of -4.1 % to a gain of 3.1 % It is not clear why there is such a large variation. Possible explanations can be different patient inclusion criteria and different measurements methods (as also mentioned in the introduction in "Limitations of endothelial cell counts"), but they are not mentioned in all publications. Additionally, the calculations do not correct for the cells that were lost due to the surgery. This negatively affects the percentages.

#### Progressive cell loss on long term?

It is inevitable that short term cell loss will occur after PJOL implantation due to the surgical procedure. It is more important that placement of a PIOL does not induce ECC loss in the long term. Therefore, the literature was evaluated again to see whether cell loss stabilized in time or was progressive. ECC was defined as stable when the annual cell loss did not exceed the physiologic loss of 0.6% at the last known year of follow-up.

Analysis of the data showed that in 9 out of 20 patient groups (45%), the cell count was stable at the last follow-up. In the other 11 studies (55%) there was ongoing cell loss that exceeded the physiological cell loss. Based on these inconsistent results, a conclusion cannot be drawn about the influence of the Artisan on the endothelium on the long term.

## Results put in perspective: comparison with ICL

### ICL far from endothelium

To put the Artisan cell loss percentages in perspective, the annual cell loss of ICL in literature is also determined. A difference between the ICL and the Artisan is the area of placement; the Artisan is placed in the anterior chamber of the eye and the ICL behind the iris in the posterior chamber, further away from the endothelium. The ICL lens is a good reference because this lens is thought to induce no cell loss since it is placed at a safe distance from the endothelium.

#### Literature search

The same selection criteria for the ICL literature search were used as for Artisan. Only seven articles were found that applied to the selection criteria (table 3). This is probably due to the fact that ICL is not thought to be related with endothelial cell loss; on international podiums, endothelial cell loss after ICL implantation is also not a topic that is being discussed.

Table 3 Overview of ICL literature. Publications in bold are n > 50.

First author:	Publications in bold are n > 50		Annual endothelial cell density change (%)
Kamija <sup>1</sup>	4	<b>56</b>	-3.71 (-0.94)
Jimenez-Alfaro <sup>1</sup>	2	5	-6.57 (-1.34)
Pesando <sup>1</sup>	<b>10</b>	<b>57</b>	-4.7 (-0.48)
Pineda-Fenandez <sup>19</sup>	3	<b>10</b>	-6.09 (-2.07)
Lackner <sup>10</sup>	3	<b>66</b>	-2.45 (-0.82)
Dejaco-Ruhswurm <sup>1</sup>	4	<b>11</b>	-12.37 (-1.25)
Edelhauser <sup>22</sup>	4	<b>57</b>	-9.7 (-2.52)

#### Results

The average annual cell loss for ICL in literature was -1.92% which is 0.35% more than Artisan (table 4). This is a remarkable result against expectations. It has to be noted that 3 studies with a small patient group greatly influence this percentage.<sup>1,19,22</sup> When these studies are omitted from the analysis and only studies are taken into account with more than 50 eyes, the annual cell loss is -1.19%. When this selection criterion is also applied for the Artisan articles, the annual cell loss is -1.18%, an almost identical percentage.

This data shows that the assumption that ICL induces less endothelial cell loss than Artisan is not supported by literature.

#### Surgery related or progressive cell loss?

Because of the positioning of the ICL, endothelial cell loss is thought to be induced only by the surgical procedure. Therefore it can be suspected that the cell density would stabilize after time. In 5 out of 7 articles (71 %) this is the case. Only in the articles of Kamija<sup>1</sup> and Jimenez-Alfaro<sup>1</sup> the cell density was not stable at the last follow-up.

Table 4: Mean endothelial cell loss after ICL implantation as presented in literature.

Number of groups	7
Mean annual EC change	-1.92 % ± 1.18
Mean annual EC change (studies n>50)	-1.19% ± 0.91
Range	-0.48 to -3.34%

#### FDA

Studies presented to the FDA can perhaps be considered less biased in endothelial cell count results than most other multicenter studies, since all endothelial cell counts are analyzed with the same standardized method. Therefore, in addition to results of the above analysis based on literature, the minimum required ECD by the FDA were compared for Artisan and ICL. It is remarkable that in the patient inclusion criteria published on the FDA website, the minimum required ECD for Artisan is lower than for ICL (3550 cells/mm<sup>2</sup> versus 3875 cells/mm<sup>2</sup> for people aged 21-25 for Artisan and ICL respectively).<sup>10</sup> This indicates that the amount of cell loss found by the FDA was lower in the Artisan group than in the ICL group. In fact, the Artisan FDA study showed a mean endothelial cell density change of -4.8% 3 years post-operative, whereas the mean ECD change in ICL was -8.4% to -9.7% two years post-operative."



## Dicussion / Conclusion

### Cell loss put in perspective

The percentages cell loss as reported in literature are inconsistent. This illustrates the difficulty of drawing proper conclusions about endothelial cell loss after Artisan implantation.

What are the risks for long term safety of the endothelium if cell loss does not stop? The article of Doors et al. mentions that an annual cell loss of 1% is acceptable<sup>14</sup>. The percentage loss that is found in this literature search is slightly higher, but still acceptable. For instance when a young patient with approximately 3000 endothelial cells/mm<sup>2</sup> receives an Artisan lens, it takes 49 years to drop to 1500 cells/mm<sup>2</sup> (including 10% surgery related loss) based on yearly loss of 1.8%. This is a safe amount for cataract surgery. If the patient starts with 2000 cells/mm<sup>2</sup>, it takes 15 years to reach 1500 cells/mm<sup>2</sup> and 49 years to reach 1000 cells/mm<sup>2</sup> (safety norm in ISO 11979-10:2006 is 1000 cells/mm<sup>2</sup> at the age of 72).

### Corneal complications in literature

To our knowledge there are 4 case reports in literature since the year 2000 about severe corneal complications due to induced cell loss after Artisan implantation.<sup>24-25-26-27</sup> In the reviewed articles, only the article of Guell reports on cases (3 cases, 0.75%) in which the lens needed to be explanted due to high cell loss, probably because of excessive eye rubbing. Although these are serious complications, the frequency in which they occur does not indicate that the lens is not safe. When the high amount of lenses that are implanted in the last ten years are taken into consideration, these reported cases can be considered incidents and percentages are negligibly small.

### Artisan versus ICL

The ICL is considered as safe for the endothelium by many surgeons. Therefore, Artisan results were compared with ICL results. The literature search showed that on average, Artisan does not induce more cell loss than ICL in the first several years after implantation, but stabilization of the cell loss was found to occur more frequently after ICL than after Artisan implantation. This is an indication that in the long-term ICL might induce less cell loss than Artisan. There are however no comparative long term publications to support this.

### Conclusion

In conclusion:

- 1) There is a lot of variation in different studies,
- 2) The average cell loss found in literature is acceptable,
- 3) The cell counts stabilize in approximately half of the publications,
- 4) The FDA requires higher preoperative cell counts for ICL than for Artisan implantation.

All this considered; the Artisan lens is safe for the endothelium when combined with proper patient selection. Patients should have a sufficient cell count before surgery and patients age should be taken into account. Furthermore small anterior chambers are a contraindication for implantation and patients should be instructed not to rub their eyes.

For a complete overview of indications and contraindications, see training manual.

## References

1. Asano-Kato N, Toda I, Hori-Komai Y, Sakai C, Fukumoto T, Arai H, Dogru M, Takano Y, Tsubota K. Experience with the Artisan phakic intraocular lens in Asian eyes. *J Cataract Refract Surg* 2005; 31(5):910-5.
2. Benedetti S, Casamenti V, Benedetti M. Long-term endothelial changes in phakic eyes after Artisan intraocular lens implantation to correct myopia. Five-year study. *J Cataract Refract Surg* 2007; 33(5):784-90.
3. Oell JL, Morral M, Gris Q, Gaytan J, Sisquella M, Manero. Five-Year Follow-up of 399 Phakic Artisan-Verisyse Implantation for Myopia, Hyperopia, and/or Astigmatism. *Ophthalmology* 2008; 115(6):1002-12.
4. Landesz M, van Rij G, Luyten G. Iris-claw phakic intraocular lens for high myopia. *J Refract Surg*. 2001; 17(6):634-40.
5. Menezo J, Peris-Martinez C, Cisneros AL, Martinez-Costa R. Phakic intraocular lenses to correct high myopia: Adatomed, Staar, and Artisan. *J Cataract Refract Surg* 2004; 30(1):33-44.
6. Moshirfar M, Holz HA, Davis DK. Two-year follow-up of the Artisan Verisyse iris-supported phakic intraocular lens for the correction of high myopia. *J Cataract Refract Surg* 2007; 33(8):1392-7.
7. Tahzib NG, Nuijts RM, Wu WY, Budo C. Long-term Study of Moderate to High Myopia: Ten-Year Follow-up Results. *Ophthalmology* 2007; 114(6):1133-42.
8. Tehrani M, Dick HB. Endothelial cell loss after toric iris-fixated phakic intraocular lens implantation: three-year follow-up. *J Refract Surg*. 2007; 23(2):172-7.
9. Saxena R, Boekhoorn SS, Mulder PG, Noordzij B, Rij GV, Luyten GP. Long-term Follow-up of Endothelial Cell Change after Artisan Phakic Intraocular Lens Implantation. *Ophthalmology* 2008; 115(4):608-13.
10. Silva RA, Jain A, Manche EE. Prospective long-term evaluation of the efficacy, safety, and stability of the phakic intraocular lens for high myopia. *Archives of Ophthalmology* 2008; 126(6):775-81.
11. Bartels MC, Saxena R, van der Berg TJJP, van Rij G, Mulder PGH, Luyten GPM. The influence of incision-induced astigmatism and axial lens position on the correction of myopic astigmatism with the Artisan Toric Phakic Intraocular Lens. *Ophthalmology* 2006; 113(7):1110-7.
12. Bartels MC, Santana NI, Budo C, van Rij G, Mulder PG, Luyten GP. Toric phakic intraocular lens for the correction of hyperopia and astigmatism. *J Cataract Refract Surg* 2006; 32(2): 243-9.
13. Saxena R, Landesz M, Noordzij B, Luyten GPM. Three-year Follow-up of the Artisan Phakic Intraocular Lens for Hypermetropia. *Ophthalmology* 2003; 110:1391-95.
14. Doors M, Cals DWJK, Berendschot TJJM, De Brabander J, Hendrikse E, Webers CAB, Nuijts RMMA. Influence of anterior chamber morphometrics on endothelial cell changes after phakic intraocular lens implantation. *J Cataract Refract Surg* 2008; 34: 2110-8.
15. Qasem Q, Kirwan C, O'Keefe M. 5-Year Prospective Follow-Up of Artisan Phakic Intraocular Lenses for the Correction of Myopia, Hyperopia and Astigmatism. *Medical technology* 2010; 224(5):283-90.
16. Kamiya K, Shimizu K, Igarashi A, Hikita F, Komatsu M. Four-year follow-up of posterior chamber phakic intraocular lens implantation for moderate to high myopia. *Arch Ophthalmol*. 2009 Jul;127(7):845-50.
17. Jimenez-Alfaro I, Benitez de Castillo JM, Garcia-Feijo J, Gil de Bernabe JG, Serrano de la Iglesia JM. Safety of posterior chamber phakic intraocular lenses for the correction of high myopia: anterior segment changes after posterior chamber phakic intraocular lens implantation. *Ophthalmology*. 2001 Jan;108(1):90-9.
18. Pesando PM, Ghiringhelo MP, Di Meglio G, Fanton G. Posterior chamber phakic intraocular lens (ICL) for hyperopia: ten-year follow-up. *J Cataract Refract Surg*. 2007 Sep;33(9):1579-84.
19. Pineda-Fernandez A, Jaramillo J, Vargas J, Jaramillo M, Jaramillo J, Galindez A. Phakic posterior chamber intraocular lens for high myopia. *J Cataract Refract Surg*. 2004 Nov;30(11):2277-83.
20. Lackner B, Pieh S, Schmindinger G, Simader C, Franz C, Dejaco-Ruhswurm I, Skorpik C. Long-term result of implantation of phakic posterior chamber intraocular lenses. *J Cataract Refract Surg*. 2004 Nov;30(11):2269-76.
21. Dejaco-Ruhswurm I, Scholz U, Pieh S, Hanselmayer G, Lackner B, Italon C, Ploner M, Skorpik C. Long-term endothelial changes in phakic eyes with posterior chamber intraocular lenses. *J Cataract Refract Surg*. 2004 Nov;30(11):2269-76.
22. Edelhauser HF, Sanders DR, Azar R, Lamielle H. Corneal endothelial assessment after ICL implantation. *J Cataract Refract Surg*. 2004 Mar;30(3):576-83.
23. Bourne WM. Morphologic and functional evaluation of the endothelium of transplanted human corneas. *Trans Am Ophthalmol Soc*. 1983;81:403-50.
24. Ioannides A, Nartey I, Little BC. Traumatic dislocation and successful re-enclavation of an Artisan phakic IOL with analysis of the endothelium. *J Refract Surg*. 2006 22(1): 102-3.
25. Guy Kleinmann, David J. Apple, Richard J. Mackool. Recurrent iritis after implantation of an iris-fixated phakic intraocular lens for the correction of myopia: Case report and clinicopathologic correlation. *J Cataract Refract Surg*. 2006 32(8): 1385-7.
26. de Sanctis U, Mutani B, Grigololo BM. Long-term endothelial cell loss after traumatic dislocation and repositioning of Artisan phakic IOL. *J Refract Surg*. 2008 24(5):546-8.
27. Kim M, Kim JK, Lee HK. Corneal endothelial decompensation after iris-claw phakic intraocular lens implantation. *J Cataract Refract Surg*. 2008 34(5):517-9.
28. [http://www.schepens.harvard.edu/joyce/research\\_story.html](http://www.schepens.harvard.edu/joyce/research_story.html)
29. Bourne WM, Nelson IR, Hodge DO. Central corneal endothelial cell changes over a ten-year period. *Invest Ophthalmol Vis Sci* 1997;38:779-82.
30. [http://www.accessdata.fda.gov/cdrh\\_docs/pdf/1/P030028c.pdf](http://www.accessdata.fda.gov/cdrh_docs/pdf/1/P030028c.pdf)
31. [http://www.accessdata.fda.gov/cdrh\\_docs/pdf/1/P030016c.pdf](http://www.accessdata.fda.gov/cdrh_docs/pdf/1/P030016c.pdf)
32. Stulting RD, et al. Three-Year results of the Artisan Verisyse phakic intraocular lens implantation. Results of the United States Food and Drug Administration Clinical Trial. *Ophthalmology* 2008;115:464-472.
33. Sanders DR, Doney K, Pico M. ICL in Treatment of Myopia Study Group. United States Food and Drug Administration clinical trial of the Implantable Collamer Lens (ICL) for moderate to high myopia: three-year follow-up. *Ophthalmology*. 2004 Sep;111(9):1683-92.

## OPHTEC BV

RO. Box 398  
9700 AJ Groningen  
Schweitzerlaan 15  
9728 NR Groningen  
The Netherlands

T: +31 50 525 1944  
F: +31 50 525 4386  
E [info@ophtec.com](mailto:info@ophtec.com)

Order lines in  
The Netherlands:  
T: +31 50 527 5400  
F: +31 50 527 4996

[www.ophtec.com](http://www.ophtec.com)

## OPHTEC Subsidiaries

### OPHTECUSA

T 00 1561 9898767  
[info@usa.ophtec.com](mailto:info@usa.ophtec.com)

### OPHTEC Espana SL

T 00 34 91 625 26 99  
[info@es.ophtec.com](mailto:info@es.ophtec.com)

### OPHTEC South Africa (Pty) Ltd

T 0027 105903135  
[info@sa.ophtec.com](mailto:info@sa.ophtec.com)

### OPHTEC Asia-Pacific CO, Ltd

T 00 852 28871762  
[info@ap.ophtec.com](mailto:info@ap.ophtec.com)

### OPHTEC Japan

T 00 81359194 366  
[info@ap.ophtec.com](mailto:info@ap.ophtec.com)

### OPHTEC Korea

T 00 82 2 508 0522  
[info@kr.ophtec.com](mailto:info@kr.ophtec.com)

### OPHTEC Germany, GmbH

T 00 49 40 60096978  
[info@de.ophtec.com](mailto:info@de.ophtec.com)

### OPHTEC Portugal

Exce/entetitulo-Unipessoa/ LDA  
T +351 9151 41958  
[info@prt.ophtec.com](mailto:info@prt.ophtec.com)

### Department OPHTEC Be/g,um

T +31 50 527 5400  
[info@be.ophtec.com](mailto:info@be.ophtec.com)



[www.facebook.com/loph tee](http://www.facebook.com/loph tee)



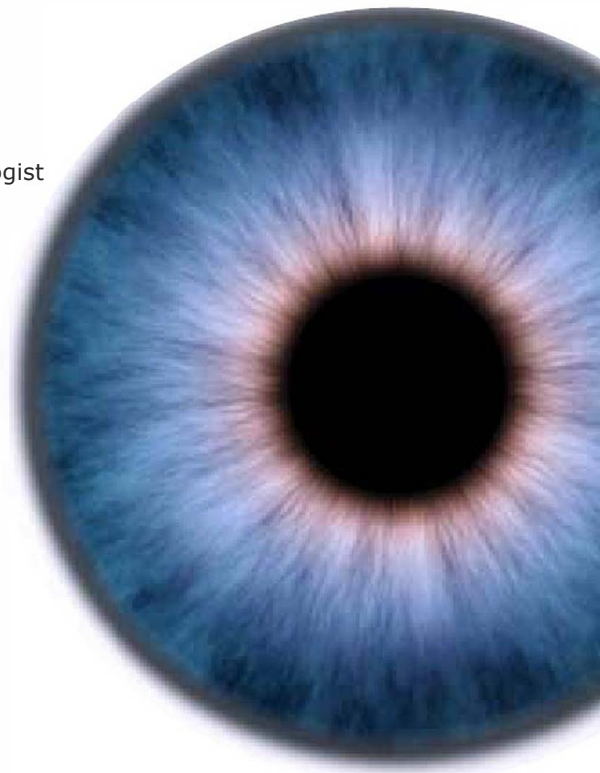
[www.youtube.com/loph tecbv](http://www.youtube.com/loph tecbv)

# Why the Iris?

// Iris is the "toughest" tissue within the eye - today many ophthalmologist cut iris tissue to reduce glaucoma, and more routinely ophthalmologist stretch the iris during cataract surgery to enhance visualization. The iris is a resilient tissue.

// Pigmented tissue in nature is usually associated with being "tough" - think of the bark on a tree - it is the tough outer "tissue" of the tree that protects the inner "white meat" of the tree. Pigmented tissue in nature is usually long lived and resilient.

// When we die and start to decompose, the iris will be the longest maintain tissue in the eye.



## Iris fixated IOL history not all "iris" IOLs are/were created equal

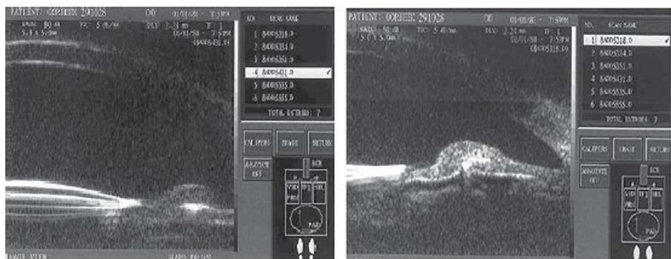
**Iris-fixated IOLs were developed as an alternative to reduce the occurrence of the problems that arose from angle fixated IOLs**

- 1950, saw several designs: iris sphincter with anterior and posterior loops. These lenses led to progressive complications and use was abandoned, because they rested/ were fixed on highly mobile lens sphincter
- Dr. Jan Worst designed the "iris claw" concept in 1978 as an aphakic lens. Making mid-peripheral fixation ideal of placing an IOL



**NOTE: iris freckle does not move with pupil dilation;  
Making mid-peripheral fixation ideal for placing an IOL**

### Artisan/Artiflex enduring technology



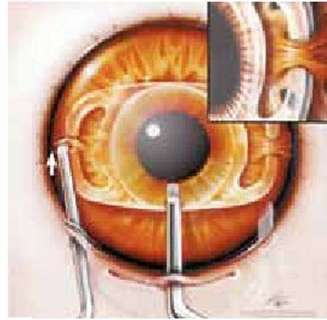
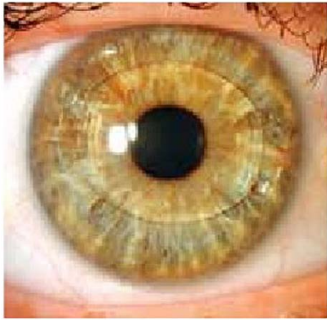
"Iris Bridge" protects the endothelium

- Claw fixation method has not changed since the introduction.
- Artisan/Artiflex claw have a fine slot to capture or enclavate a small knuckle of mid-peripheral iris that is virtually immobile.
- Artisan/Artiflex optic is bridged over the mobile iris and pupil.
- Artisan/Artiflex will NOT rotate or tilt.
- **Use of a small portion of iris for fixation has proven to create no clinical trauma.**




# ARTISAN<sup>®</sup> / ARTIFLEX<sup>®</sup> - Enduring

Proven to be one of the world's safest, most effective IOL designs, with the broadest applications of any IOL- Phakic, Secondary/Aphakic, Pediatric and Trauma



- The Artisan/Artiflex concept is now the IOL with the longest design history still in use (since 1978).
- The Artisan/Artiflex corrects hyperopia, myopia, and astigmatism, and is used routinely for aphakic, secondary, pediatric and trauma implantations.

## Endothelial cell HEALTH with ARTISAN<sup>®</sup> / ARTIFLEX<sup>®</sup>



- Cataract surgery, and all corneal incisions (laser or knife), will damage/re-model endothelial cells (see matrix of peer review data).
- Manipulation of instruments, and IOLs, during cataract surgery, do not cause undue concern with endothelial cell loss, and so it is with the Artisan lens - careful insertion is key to endothelial health.
- **With age, the number of cells decreases at a rate of 0.6% per year after age 18.** This means that after 10 years, a loss of approximately 6% could be found\*.
- In a 10 year, peer reviewed\* Artisan study, no endothelial cell loss of this magnitude was found. The data demonstrated there was **no significant long-term corneal endothelial cell loss over time.**
- **No correlation was found between endothelial cell loss at 10 years and the preoperative anterior chamber depth,** which supports the hypothesis that an anterior chamber depth of at least 3.0 mm is an adequate safety measure for the implantation of the Artisan.

\* Bourne VM, Nelson LR, Hodge DO. Central corneal endothelial cell changes over a 10-year period. Invest Ophthalmol Vis Sci 1997;38:779-82

\*\* Tahzib NG, Jha RM, Wu WY, Budo CJ. Long-term Study of Artisan Phakic Intraocular Lens Implantation for the Correction of Myopia: Ten-Year Follow-up Results. Ophthalmology 2007; 114(6):1133-42

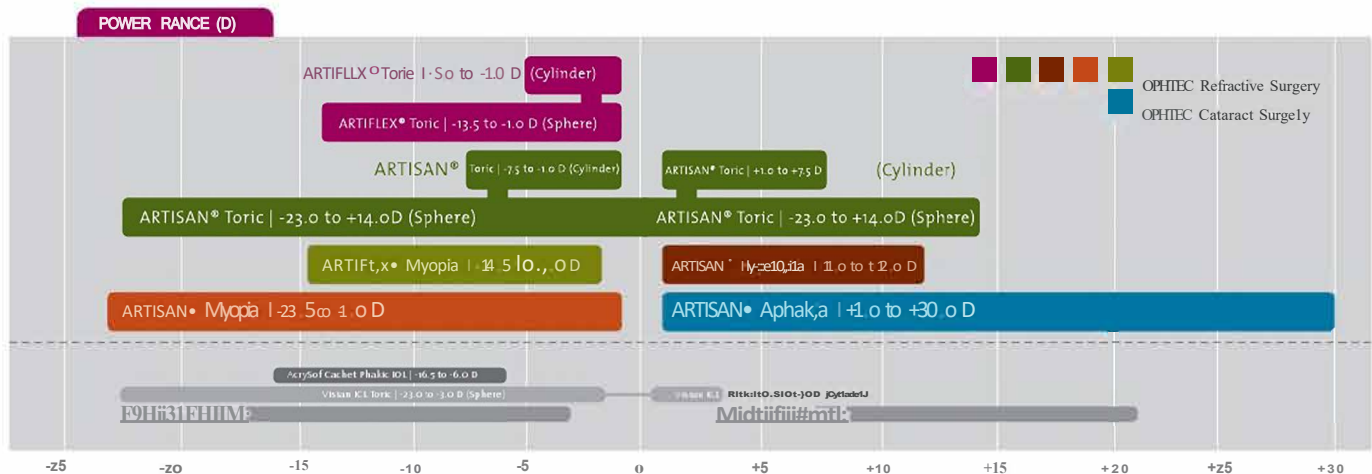
# ARTISAN® /ARTIFLEX® vs. ICL, Cachet, Natural Ageing & Standard Cataract

## Annual Endothelial cell loss

	ARTISAN/ARTIFLEX	ICL	Cachet	Cataract surgery	Natural aging
<b>Annual Endothelial cell loss</b>	Myopia, Toric and Hyperopia: 1.58%, 0.68% and 1.77% respectively 10 yrs. data <sup>1</sup>	The average annual cell loss for ICL in literature was 1.92% <sup>1</sup>	3-3% at 6 months, 11 at 5yrs. - ONLY 159 patients followed <sup>1</sup>	25% per year for at least 10 years after surgery, even without a lens implant <sup>1</sup>	adult cornea decreases at a rate of 0.6% per year <sup>•</sup>
<b>Sizing</b>	One size fits all eyes exactly	4 sizes - fits no eye exactly	4 sizes -fits no eye exactly	Sulcus issues	NA
<b>Centration</b>	Surgeon choice	Anatomy decides	Anatomy decides	NA	NA
<b>Toric stability</b>	Does not rotate or tilt. after 24hr good vision; <sup>2</sup>	Can rotate and tilt and long visual recovery <sup>1</sup> .	No Toric option	NA	NA
<b>Incision size</b>	32 / 52 / 62 mm	3.2mm	3.2mm	18 mm - 35 mm	NA
<b>Clinical History</b>	25yrs, fixation method has been unchanged	15 yrs. - design changed 5 times to address complications	5yrs.	NA	NA
<b>Control off lens position</b>	Easy to confirm	Difficult to confirm	Easy to confirm	Difficult	NA
<b>Main concern with design</b>	Surgical learning curve. requires millimeters of clearance	Sizing, centration, limited clearance in sulcus - onlymicrons of clearance in sulcus	Sizing, centration, and angle related complications	Capsule/sulcus issues	NA

1. White RP, et al. www.ophtl.com (ARTISAN and ARTIFLEX Phakic IOLs Clinical Evidence Continues to Support Biocompatibility and Design Features. Comprehensive Overview of Literature: Endothelial Cell Change after Artisan/Artiflex Implantation) 2. Alcon Cachet Field Safety Notice (taken from official study) 3. <http://www.fda.gov/oc/ohrt/402611da%20SUMMARY%20FINAL.htm> - Bourne WA, Nelson LR, Hodge DO. Annual corneal endothelial cell changes after toric phakic intraocular lenses. Invest Ophthalmol Vis Sci. 1997;38:798-815. Tehmini MJ, Dick HB, Schwenn O, Born E, Schmidt AH, Koch HR. Isoperforated astigmatism and rotational stability after toric phakic intraocular lens implantation. J Cataract Refract Surg. 2003 Sep;29(9):1161-6. 6. Mori T, Yokoyama S, Kojima T, Isogai N, Ito N, Homi R, Nakamura T, Ufukawa K. Factors affecting rotation of a posterior chamber collagen copolymer toric phakic intraocular lens. Cataract Refract Surg. 2012 Apr;38(4):568-73

## ARTISAN® /ARTIFLEX® vs. ICL & Cachet Diopter Range




# What is Quality of Vision?

## All "20/20 vision" is not equal - Why?

### Loss of contrast

Usually caused by light scatter by/thru refractive medium.  
The bottom lines on both reading charts below are 20/20 vision, but it is obvious quality of vision is different between the 2 charts.



*A retrospective study" was performed comparing Optical Quality of Irisfixated Phakic IOL versus Sulcus Fixed Phakic IOL*

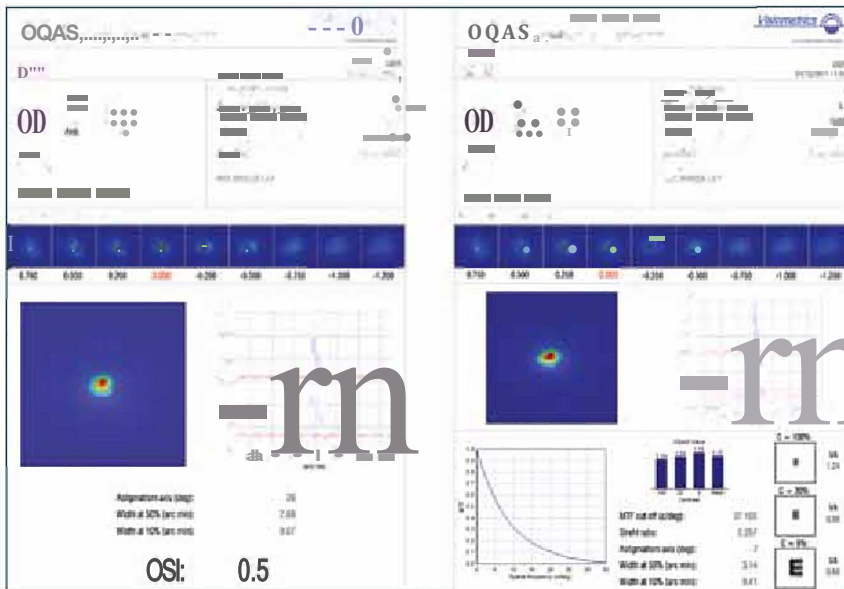
### Objective

With a validated objective tool, determine the differences in quality of vision (Optical Scatter Index (OSI)) for two different Phakic IOLs.

### Conclusion

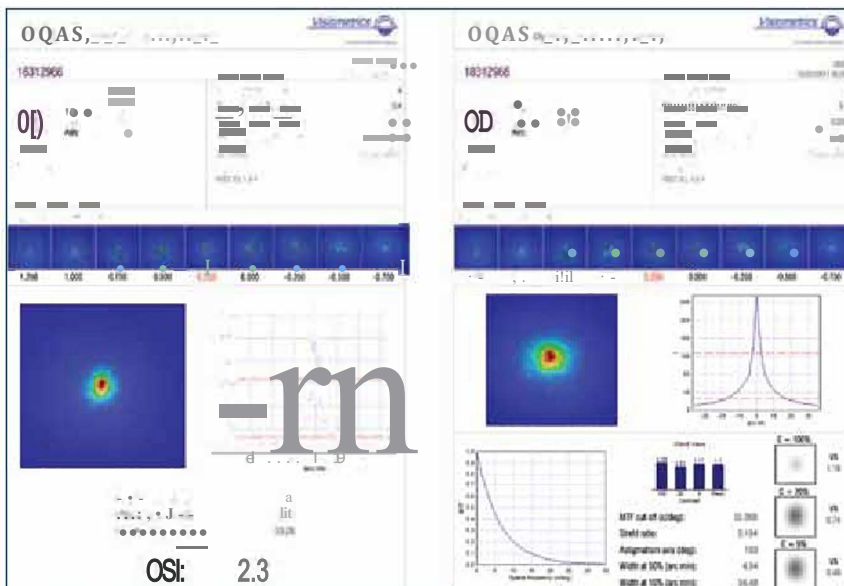
This study showed the iris fixated Phakic IOL produced the best quality of vision in all patients, and in some patients with sulcus fixated Phakic IOL the quality of vision was degraded equal to a +3 cataract.

•Pending publication; Dr. Lee, Korea



The visual acuity in these patients are nearly the same but the Quality of vision is very different. This objective data (OSI) shows the Quality of vision in the Artiflex is nearly 4 times better than ICL, even with Visual acuities that are nearly identical.

**Artiflex**  
VA - 124  
OSI= .05



**ICL**  
VA- 118  
OSI= 23

# Accommodation and Phakic IOLs

## ARTISAN / ARTIFLEX vs. ICL

### ARTISAN/ ARTIFLEX

In a 3 year post-op multicenter peer review study the distance between the posterior surface of the Artisan/Artiflex and anterior surface of the crystalline lens was measured as the patient accommodated.

The study proved the distances remained constant with accommodation - this suggests that the iris diaphragm and crystalline lens act as a unit and move forward.<sup>1</sup>

ACD decreases with accommodation as a result of the forward movement of the diaphragm iris crystalline lens. With the Artisan/Artiflex no measurement was found less than 2.0 mm at any point in the examination, which is considered the limit of safety for the corneal endothelium.<sup>1</sup>

### ARTISAN / ARTIFLEX allows natural accommodation to continue with age

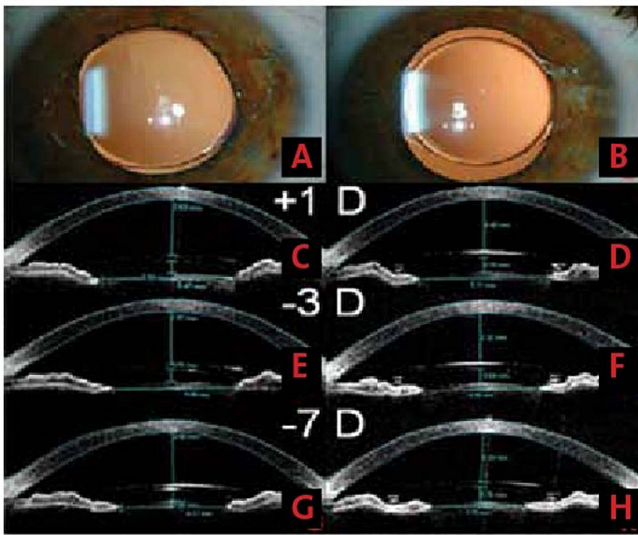


Figure 1 Clinical photographs showing ARTISAN PIOL (A) and ARTIFLEX PIOL (B) positioning in the anterior segment. C and D Visante OCT of the same patient with relaxed accommodation. Note the calipers (blue lines) used for anterior segment measurements. E and F Visante OCT of the same patient with -3.0 D of accommodation. G and H Visante OCT of the same patient with -7.0 D of accommodation.

A main concern with all Phakic IOL is how they will interact with anterior segment structures (mainly anterior chamber angle, ciliary sulcus space, corneal endothelium, and crystalline lens). Modifications in the anterior segment can occur during accommodation and throughout life, and could predispose patients to premature cataract formation as they age, and/or limit the eyes ability to accommodate. With every diopter of accommodation the anterior pole of the crystalline lens moves forward 30µm.

### ICL

When we consider ICL sizing we usually think about width and not depth of sulcus. The ICL has very critical distance tolerances - consider the ICL's ability to block the natural lens ability to accommodate. The depth of the sulcus space shrinks as we age - an ICL that "fits" at 30 yrs old may not fit at 50 yrs old

The ICL sizing criteria allows only microns of tolerance before problems can occur. The space allowance in the sulcus is very "tight".

As the ICL "sits" on top of the natural lens, it should cause hesitation considering the patient's age. The natural lens grows with age and will collide with ICL - in time. With age, during accommodation, the ICL will come into greater direct contact with the natural lens. This may cause early cataract formation, and the ICL may inhibit patient's ability to accommodate. Further studies on this subject are planned

*Jose Luis Guell, MD, Merce Morral, MD, Oscar Gris, MD, Javier Gaytan, MD, Maite Sisquet/a, Opt, Felicidad Manero, MD*  
*Evaluation of Artisan and Artiflex phakic intraocular lenses during accommodation using Visante Optical Coherence Tomography*  
*Journal of Cataract and Refractive Surgery 2007; 33(8): 1398-1404.*



# ARTISAN. APHAKIA



## #1 Backup Lens in complicated Cataract Cases

Based on the long term experience of Iris Fixation, the ARTISAN® Aphakia IOL is a predictable, safe, high precision implant, that corrects the eye when it is not correctable by other means. **Small diameter lenses are available on request for Asian eyes and pediatric cases.**



## Features & Benefits

- Iris Fixation
- One size fits all
- Long term clinical experience
- Predictable, reliable, stable
- Also fit for retro pupillary fixation
- Long term safety



Versatility; AC or PC fixation

## // Specifications

ARTISAN® Aphakic IOL		HHM - : @di4i : l:tl&if4i:i!N					Dioptric Powers	
AphakicIOL Model 205		PMMA	8-5mm	54 mm	1150 (Ultrasound) 1157 (OLMaster /Optical)	3.3mm	2.0 D to 30.0 D (1.0 increments) 145 D to 24.5 D /05 increments)	

## Artisan Aphakic Benefits Matrix

Aphakic, Pediatric, Trauma, Complications

	Artisan	Angle Supported lens	Sciera sutured PC IOL
<b>Time</b>	10-20 minutes	10-20 minutes	20 to 60+ minutes
<b>Safety</b>	Complications limited to technique	Angle related complications	Sutures can erode and refraction unstable
<b>Outcomes</b>	Excellent. predictable	Angle related complications	Refraction not predictable, lens tilt, hemorrhage and secondary glaucoma
<b>Clinical History</b>	30+ years	Removed from many markets	30+ years
<b>Toric option</b>	Yes	No	No
<b>Suturing required IOL</b>	No	No	Yes
<b>Surgical technique</b>	Easy	Easy	Complicated and extensive
<b>Fixation options</b>	Iris	Angle	Sclera, sulcus, iris

**Artisan lenses are used in case of certain complications when PC lenses cannot be used:**

- Insufficient support of the capsular bag
- Loss of capsular bag

### Trauma

### Secondary pathologies:

- Marfan's Syndrome
- Pseudoexfoliation
- Congenital cataract
- Weill-Marchesani
- Homocystinuria



# ARTISAN. Myopia and Hyperopia PIO Ls

## ARTISAN® Myopia; first FDA approved Phakic IOL worldwide (2004)

ARTISAN™ has passed the test of time by filling the need for those who seek a predictable and stable solution for the surgical correction of myopia, hyperopia and astigmatism.

### Features & Benefits



- Iris Fixation
- Reversible treatment
- Predictable, reliable, stable, versatile
- Optimal clearance from vital tissues
- Various optical zone sizes
- Long term safety

### // Specifications

ARTISAN® PIOL	Material	Total(//)	Body(//)	Dioptic Powers
ARTISAN• Myopia 5.0mm Model 206	PMMA	8.5 mm	5.0mm	-1.0 D to -2.35 D (0.5 increments)
ARTISAN• Myopia 6.0mm Model 204	PMMA	8.5mm	6.0mm	-1.0 D to -1.55 D (0.5 increments)
ARTISAN• Myopia 5.0mm Small; Model 202	PMMA	7.5mm	5.0mm	-1.0 D to -2.35 D (0.5 increments)
ARTISAN• Hyperopia 5.0mm Model 203	PMMA	8.5 mm	5.0mm	+1.0 D to +1.20 D (0.5 increments)